

Malignant Small Round Cell Tumor: A Rare Aggressive Malignancy-Case Report

Gichuki Joseph Maina¹, Loise Ndunge², Anthony Gikonyo³, Charles Masese⁴, Timothy Wachira⁵, Duncan Luvayo⁶, Premanand Ponoth⁷

¹Cardiology student, The Karen Hospital Medical Training College, The Karen Hospital, Nairobi, Kenya.

²Medical intern, The Karen Hospital Medical Training College, The Karen Hospital, Nairobi, Kenya.

³Cardiologist, The Karen Hospital Medical Training College, The Karen Hospital, Nairobi, Kenya.

⁴Lecturer, The Karen Hospital Medical Training College, The Karen Hospital, Nairobi, Kenya.

⁵Lecturer, The Karen Hospital Medical Training College, The Karen Hospital, Nairobi, Kenya.

⁶Research coordinator, The Karen Hospital, Nairobi, Kenya

⁷Chief of Cardiothoracic & Vascular surgery, The Karen Hospital Medical Training College, The Karen Hospital, Nairobi, Kenya.

ABSTRACT

Background: Malignant Small round Cell Tumor (MSRCT) is very rare group of tumors. Malignant cells have similar histologic appearance making it difficult to distinguish one from another, and poses a diagnostic challenge with needs for a multimodal approach. Immunohistochemistry and immunophenotyping by flow cytometry, reverse transcriptase polymer chain reaction (RT-PCR) and fluorescence in situ hybridization are needed to confirm. The appropriate and best treatment in early stages of MSRCT is early surgical excision with chemoradiotherapy based on patient specification. In spite of all these, tumors have poor prognosis and chance of recurrence are high.

Method: Case study of a 27-year-old male who presented with a non-productive cough for 4 weeks, with feverish feeling with weight loss and shortness of breath and a new onset precordial chest pain non radiating and worse on exertion. On examination his vitals were: BP 121/91 mm of hg, pulse rate 114bpm, temperature 36.3 degrees Celsius, respiratory rate 24/per min, SPO2 96%. On examination, Elevated Jugular Venous Pressure, hyperactive precordium, displaced apex beat to 6th intercostal space anterior axillary line, muffled heart sounds and bilateral lower limb edema. Respiratory exam was unremarkable. Sputum gene expert was negative for mycobacterium tuberculosis and covid 19 rapid test was negative. Chest X Ray showed cardiomegaly and a transthoracic echocardiography revealed moderate-large pericardial effusion, with mild collapse of right atrium in diastole. Pericardiocentesis done showed hemorrhagic effusion with lymphocytes cell component, patient was initiated on treatment for TB pericarditis empirically. Three months later a chest CT scan done revealed extensive mediastinal/pericardial mass with lung nodules. An ultrasound guided mediastinal/Pericardial biopsy was done, revealed a poorly differentiated small round cell carcinoma.

Results: Patient expired 14 weeks from the initial onset of symptoms while awaiting immunohistochemistry studies for specific diagnosis of the tumor and oncology review.

Discussion: This demonstrates the complexity of establishing differential diagnosis of MSRCT in a resource limited setting with subsequent delay in treatment initiation, heralds poor prognosis. This also confirms difficulties in establishing differential diagnosis in poorly differentiated tumor.

MATERIALS&METHODS

Malignant Small Round Cell Tumors (MSRCT) is a group of tumors composed of malignant cells that are slightly larger or double the size of red blood cells. They comprise of Ewings sarcoma, Peripheral neuroectodermal tumor, Rhabdomyosarcoma, Synovial sarcoma, non-Hodgkins's lymphoma, Retinoblastoma, Nephroblastoma, Small cell osteogenic sarcoma, Synovial sarcoma and Desmoplastic small round cell tumor¹etc. All these tumors have a similar histologic appearance, and thus hard to distinguish one from the other. The cells are blue, containing thin rim cytoplasm and large hyperchromatic nuclei². Identification of poorly differentiated tumor is difficult and thus definitive diagnosis may be impossible owing to this primitive nature. Diagnostic multimodal approach is applied in their classification and they include immunohistochemistry and immunophenotyping by flow cytometry, reverse transcriptase polymer chain reaction (RT-PCR) and fluorescence in situ hybridization³. Desmoplastic Small

Malignant Small Round Cell Tumor: A Rare Aggressive Malignancy-Case Report

Round Cell Tumor (DSRCT) should be considered as a differential in MSRCT with unusual histology at any odd site. There is only one case of excised desmoplastic small round cell tumor involving the pericardium and extending into the heart has been reported with poor outcome⁴. The appropriate and best treatment in early stages of MSRCT is early surgical excision with chemoradiotherapy based on patient characterization. However, these tumors have recurrences and poor prognosis despite multimodal approach¹.

CASE REPORT

27-year-old male presented on 11/12/ 2021 with a non-productive cough for 4 weeks, chest pain, weight loss with feverish feeling. Chest pains were precordial and worse on exertion, non-radiating, and associated with shortness of breath. There was no history of diaphoresis, palpitations, syncope, sudden death in the family or family history of cardiovascular diseases. There was no history of contact with known TB patient.

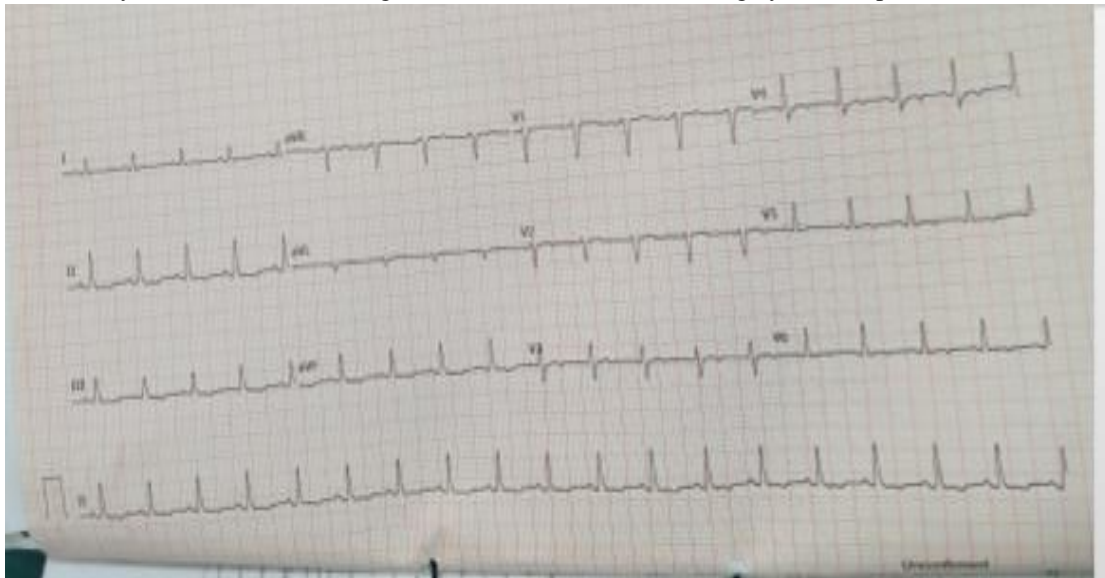
Vitals were Blood Pressure 121/91mmhg, pulse rate 114b/min regular, Temperatures 36.3-degree Celsius, respiratory rate 24b/min, spo₂ 96% on room air.

Systemic examination showed bilateral lower limb edema along with Elevated Jugular Venous Pressure, hyperactive precordium, displaced apex beat 6th intercostal space, anterior axillary line, muffled heart sounds with no added sound.

Normal Vesicular breath sounds heard in the lung field.

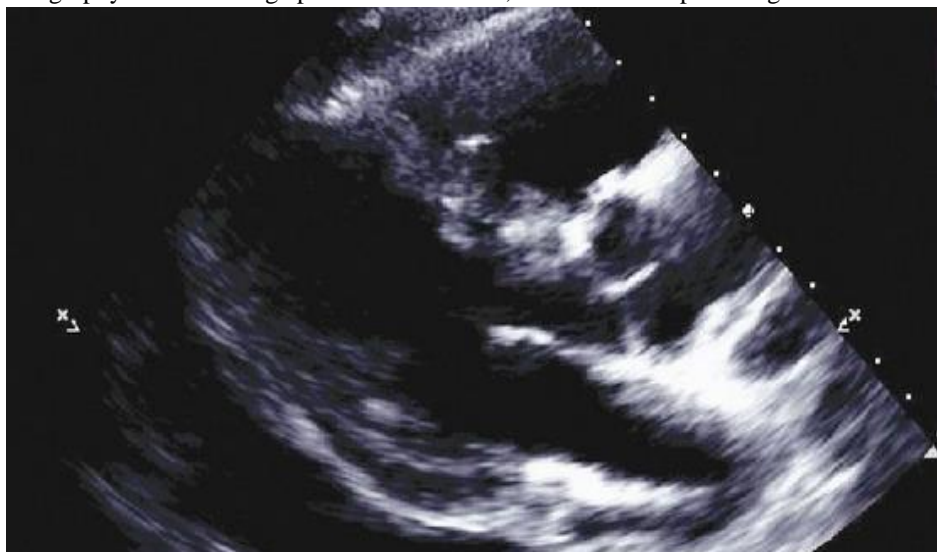Investigations: Complete blood count: WBC 6500 cells/microliter, Platelets 602cells/microliter, ESR 56mm/hr.(0-20mm/hr.), C-Reactive Proteins 83.1mg/L(<10mg/L) glycated hemoglobin 5%, Covid 19 rapid test negative.

ECG showed Sinus tachycardia 120b/min and regular and CXR showed cardiomegaly with no pleural effusion.



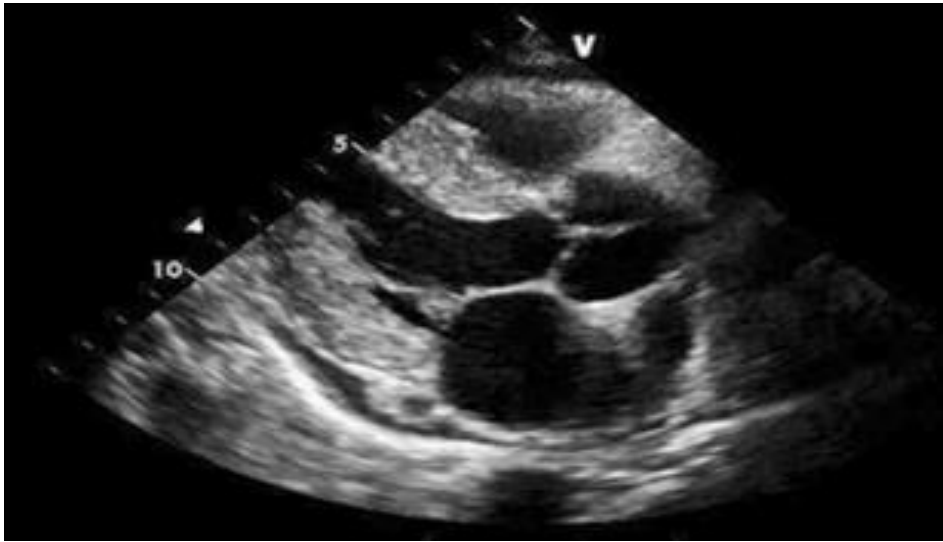
ECG 1. 11/12/2021-sinus tachycardia, diffuse T wave inversion II,aVF,V2-6;positive T wave aVR,V1(reciprocal changes)

Transthoracic echocardiography showed a large pericardial effusion, with mild collapse of right atrium in diastole.



ECHO 1.11/12/2021-Large pericardial effusion

Malignant Small Round Cell Tumor: A Rare Aggressive Malignancy-Case Report



ECHO 2. 15/12/2021-mild pericardial effusion after Pericardiocentesis

Sputum gene expert done showed negative for mycobacterium tuberculosis.

Pericardiocentesis was hemorrhagic, with lymphocytes cell component, no growth on culture and negative Ziehl- Neelsen staining. A differential diagnosis of TB pericarditis was made and patient was started on:

Amoxicillin/clavulanic acid 1gm 12 hourly x 5days

Colchicine 500mcg 12 hourly x 3 months

Frusemide 40mg once daily,

Carvedilol 12.5mg 12 hourly

Prednisolone 15mg 8 hourly x 2 weeks

Anti tuberculosis Medication.

Vitamin B 6: Pyridoxine 25mg once daily.

A repeat Echo after 3 days had mild effusion, LVEF 66%. Patient was discharged on above oral medications through cardiology outpatient clinic for review in two weeks. No episode of fever was ever recorded during the inpatient stay.

Patient reported back on 26/01/2022, presenting with 4 days history of worsening cough, severe chest pains, shortness of breath and intermittent feverish feeling.

He was looking sick and was breathless. Blood pressure 116/80mmhg, Pulse Rate 112b/min regular, Respiratory Rate 24b/min, Spo2 90%, Temperatures 36 degrees Celsius. He had Distended Jugular Veins with normal apex, no murmur was heard. On auscultation had Bilateral lung crepitations. Echocardiography showed good biventricular systolic and diastolic function, Ejection Fraction 60%, constrictive pericardium with mitral inflow variations with respirations. Chest X-ray showed widened mediastinum with lung opacities were seen.

Provisional diagnosis of constrictive pericarditis due to Post TB was concluded., and was treated with IV medication as in patient. ceftriaxone 1gm 12 hourly x 5 days Aldactone 25mg morning, iv furosemide 80mg morning, Carvedilol 12.5mg 12 hourly and RHZE 4 tabs od, po pyridoxine 25mg od, po prednisolone 15mg bd and iv paracetamol 1gm tid.

Chest CT scan was done and revealed an extensive mediastinal/pericardial mass with lung nodules, an ultrasound guided mediastinal/Pericardial biopsy was done on 14th March revealed, a poorly differentiated small round cell carcinoma. Sample was sent for IHC studies.

Patient expired On 18/03/2022 while awaiting IHC studies for specific diagnosis of the tumor and oncology review. Throughout the inpatient stay patients' vitals remained within the normal ranges. IHC was non diagnostic.

DISCUSSION

Malignant small round cell tumors are highly malignant tumors and they include a group of tumors with similar histologic appearance making it difficult to differentiate them owing to their primitive nature¹. Though primary pericardial and mediastinal tumors are very rare; they may be benign or malignant⁵. Pericardial benign tumors include pericardial cysts and lipomas while mesothelioma is the commonest malignant pericardial tumor. Other malignant pericardial neoplasms include the sarcomas, primitive neuroectodermal tumors, desmoplastic small round cell tumor and lymphoma. The common complaints are nonspecific such as chest pain, dyspnea, dizziness, weight loss, fevers and palpitations⁵.

Malignant Small Round Cell Tumor: A Rare Aggressive Malignancy-Case Report

Desmoplastic small round cell tumor should be considered as a differential in MSRCT occurring at unusual locations⁴. It's a highly aggressive tumor that affects young males and requires robust studies to diagnose using immunohistochemical characteristics. It has its main primary site in the abdomen or pelvis with a median survival duration of 26 months⁶.

There are high chances of MSRCT recurrency after treatment, equally there is obvious complexity in our setting in identifying the differential diagnosis which delays initiation of anticancer treatment to the patient. While having a specific and a highly effective narrowly targeted therapy is what would be most desirable, and it reduce the chances of a relapse.

Pericardial effusions are common in clinical practice and are from different etiologies like heart diseases, trauma, kidney disease, infection, autoimmune, malignancies and iatrogenic. Large pericardial effusions are cancerous in 10-20% cases. Pericardial effusion secondary to malignancy indicates poor prognosis and its management requires multidisciplinary team⁷. While Chest radiograph forms the first line of investigative modality as well as transthoracic echocardiography, they do not give clear details of mediastinal and pericardial tumors thus making their value limited. Cardiac CT scan is able to characterize cardiac tumors including the ability to delineate whether the tumor is solely on the pericardial surface or there is extension into the pericardial sac, myocardium and the chambers⁸. However, echocardiography remains the gold standard for evaluation of pericardial effusion⁹. Studies have shown that tumors are a source of fever. It is usually intermittent with an unclear pathophysiology, accounting for about 27% of noninfectious fever. One of the hypothesis surrounding neoplastic fever is the role of interleukins (IL-1,6,8); Interferon gamma and Tumor Necrosis factor alpha⁷. These are endogenous cytokines with pyrogenic effects through increasing synthesis of prostaglandin E2 via the endocannabinoid dependent pathway. Prostaglandin E2 modulates hypothalamus temperature set point via EP3 receptors¹⁰.

CONCLUSION

This case report demonstrates the delay of establishing differential diagnosis of MSRCT in a resource scarce setting. It also confirms difficulties in establishing differential diagnosis in poorly differentiated tumor.

This calls for appropriate equipping of our hospitals with immunophenotyping studies for early diagnosis and treatment.

It is vital to be aggressive in excluding a malignancy in any large pericardial effusion and not just limit to tuberculosis despite TB pericarditis being the commonest cause in Africa.

REFERENCES

- 1) Colak, O. et al. (2018) A Rare Tumor, a Rare Localization: A Malignant Small Round Cell Tumor in the Thigh. *European Archives of Medical Research*, 34(3), pp. 200–203. doi: 10.5152/eamr.2018.46503.
- 2) Mohammadzaman, H. et al. (2021). Malignant Small Blue Round Cell Tumor- A Case Report. *Oral & Maxillofacial Pathology Journal*, 12(2), pp. 84–86.
- 3) Rajwanshi, A., Srinivas, R., & Upasana, G. (2009). Malignant small round cell tumors. *Journal of cytology*, 26(1), 1–10. <https://doi.org/10.4103/0970-9371.54861>
- 4) George, S. et al. (2007). Malignant small round cell tumor of the heart: a diagnostic dilemma. *Cardiovascular Pathology*, 16(1), pp. 56–58. doi: 10.1016/j.carpath.2006.09.004.
- 5) Restrepo, C. S. et al. (2013). Primary pericardial tumors. *Radiographics*, 33(6), pp. 1613–1630. doi: 10.1148/rg.336135512.
- 6) Xiang, T. et al. (2020) A nationwide analysis of desmoplastic small round cell tumor. *Medicine*, 99(30), p. e21337. doi: 10.1097/MD.00000000000021337
- 7) Adegboye, V. O. et al. (2003) 'Presentation of primary mediastinal masses in Ibadan', *East African Medical Journal*, 80(9), pp. 484–487. doi: 10.4314/eamj.v80i9.8747.
- 8) Shartouni, Ranimet al. (2022) The Value of Cytology in the Evaluation of Malignant Pericardial Effusions: A Systematic Review. *Diagnostics*, 12(2). doi: 10.3390/diagnostics12020367
- 9) Godwin, J. D. et al. (no date) CASE REPORTS Computed Tomography: A New Method for diagnosing tumor of the heart. *AHA journals* pp. 448–451
- 10) Imazio, M. et al. (2010) 'Triage and management of pericardial effusion', *Journal of Cardiovascular Medicine*, 11(12), pp. 928–935. doi: 10.2459/JCM.0b013e32833e5788.
- 11) Conti B. (2016). Prostaglandin E2 that triggers fever is synthesized through an endocannabinoid- dependent pathway. *Temperature (Austin, Tex.)*, 3(1), 25–27. <https://doi.org/10.1080/23328940.2015.1130520>